

Case Report Article

Endodontic treatment of internal root resorption: a case report

Carla Frehner Andrade¹
Nathaly Dias Morais¹
Luciana Stadler Demenech¹
Flávia Sens Fagundes Tomazinho¹
Flares Baratto-Filho¹
Denise Piotto Leonardi¹
Bruno Marques da Silva¹

Corresponding author:

Bruno Marques da Silva
Rua Pedro Viriato Parigot de Souza, n. 5.300 – Campo Comprido
CEP 81280-330 – Curitiba – PR – Brasil
E-mail: brunoendodontia@gmail.com

¹ Department of Dentistry, Positivo University – Curitiba – PR – Brazil.

Received for publication: November 29, 2015. Accepted for publication: March 16, 2016.

Keywords: internal root resorption; dental trauma; calcium hydroxide.

Abstract

Introduction: Root resorption, usually found through radiographic examinations is an internal or external injury. Since root resorption is a multidisciplinary problem, it requires a variety of knowledge for understanding the etiology and pathogenesis of the disease. **Objective:** This study aimed to demonstrate the importance of how a correct and early diagnosis facilitates the evaluation of the best treatment for each case, assuring a favorable prognosis. **Case report:** A radiographic finding in a 25-year-old young male showed the presence of an internal root resorption and apical periodontitis in tooth #22. After endodontic therapy and monthly calcium hydroxide dressing changes, the root canal filling was conducted and the case was radiographically followed-up. **Conclusion:** An accurate initial examination, with a carefully detailed anamnesis and periapical radiographs are vital points for a correct diagnosis, treatment and, consequently, a better prognosis favoring the success of the case.

Introduction

The root resorption can be classified into physiological and pathological. Physiological resorption occurs in primary teeth as part of the normal process of the rhizolysis. In permanent teeth, the resorptions are always pathological, as there is no physiological root resorption in them [12]. Pathological resorptions can be classified into internal and external, and also the combination of them [4].

External root resorption shows the continuity of root canal, which may start as delayed reaction to dental trauma, as a result of orthodontic movement, orthognathic surgery, periodontal treatment, and tooth whitening without pulp vitality. Their exact pathogenesis is still unknown, being called idiopathic if no etiological factor is identified [4]. Radiographically, it presents as a radiolucent area of uneven edges found at different heights of the root, maintaining the contour of the pulp pre dentin. At more advanced stages, the affected teeth may have mobility, fracture or a pink coloring injury in the crown [4].

External root resorption which often is related to orthodontic treatment, so-called surface resorption, can be observed radiographically as a round root apex. Although representing an idiopathic problem, it influences on the benefits of a successful therapy without compromising the longevity of teeth involved [1]. In most cases, the teeth were asymptomatic and may occasionally exhibit a small mobility, as well as sensitivity to percussion [4].

On the other hand, the internal resorption is characterized by the resorption of the inner surface of the root canal in vital teeth, usually triggered by a chronic pulpitis or trauma causing the formation of dentinoclasts (cells responsible for resorption). Normally, it is also asymptomatic (radiographic findings) and reaches any region of the root canal, including the coronary portion. When in the root, it is observed that the boundary limits of the pulp undergoes relatively symmetric expansion with regular and rounded contours. In some cases, it can be observed a formation of a barrier against the resorption, triggered by odontoblasts in a portion of the non-mineralized tissue, causing injury and loss of pre-dentine layer. In cases of trauma, focal displacements of the predentin and also of the odontoblast layer occur [4].

Even if the internal resorption is triggered by the pulp own structure, or by the structure close to the pulp, it does not induce pulp necrosis, because the process of resorption releases no toxic products to

the cells [5]. At the moment that the total necrosis of the pulp occurs, the internal resorption process stabilizes, initiating the formation of a periapical lesion [13].

A suitable differential diagnosis between the internal and external cervical resorption is essential because each case presents different pathological processes and requires different treatment protocols [11]. The differential radiographic diagnosis of root resorption often has small features difficult to identify. One should always associate the radiographic with clinical findings and also the medical history reported by the patient and, in cases where there is still doubt, indicate the use of computed tomography, thus favoring the case prognosis [8].

This study aimed to report a case of internal root resorption which showed a favorable prognosis due to early diagnosis and appropriate choice of endodontic treatment followed by a satisfactory endodontic filling.

Case report

Patient F. T. F. S., Caucasian, male, aged 25 years, sought a private practice for routine radiographic examination. The anamnesis revealed no systemic change. Clinically, the periodontal tissue was normal, but many teeth had carious lesions: #17 (O), #16 (MO), #26 (MOV), #27 (O), #47 (MOV), and #46 (ODV). Radiographically (figure 1), the maxillary anterior region showed the presence of an extensive restoration, internal root resorption, and apical periodontitis in tooth #22. The patient reports he did not remember trauma history in the region. Considering the clinical and radiographic diagnosis (-50°C), it was found that the pulp of tooth #22 underwent necrosis, indicating a need for endodontic therapy

The patient was submitted to local anesthesia with mepivacaine 2% (Mepinor, Nova DFL, Rio de Janeiro, RJ, Brazil) on the papilla for inserting the clamps. After rubber dam isolation, crown access was performed with the aid of round diamond bur #1014 (KG Sorensen, Cotia, SP, Brazil). After the radiographic odontometry (figure 2), hand instrumentation was performed with reverse (crown-down, cervical-apical, crown-apex). The working length (WL) was of 23 mm, and the surgical diameter (SD) was obtained with a K file #70. After proper disinfection and irrigation of root canal with 2.5% sodium hypochlorite (Cloro Rio 2.5%, Rioquímica, São José do Rio Preto, SP,

Brazil), a intracanal dressing with calcium hydroxide powder. (Biodinâmica, Ipirorã, PR, Brazil) mixed with 0.9% saline solution (Fisiosol, Riberão Preto, SP, Brazil). The tooth was sealed with provisional material (Villevie, Joinville, SC, Brazil).

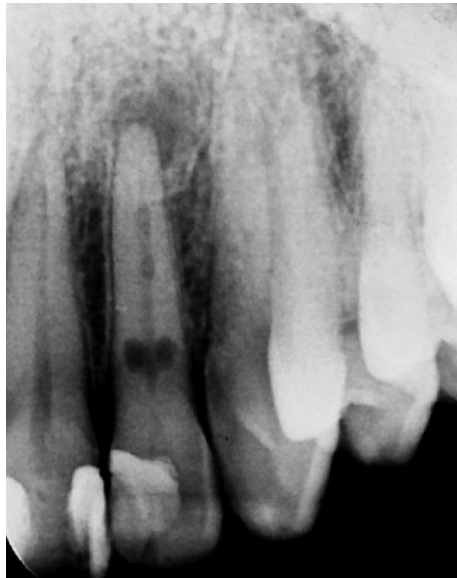

Figure 1 - Initial radiographic

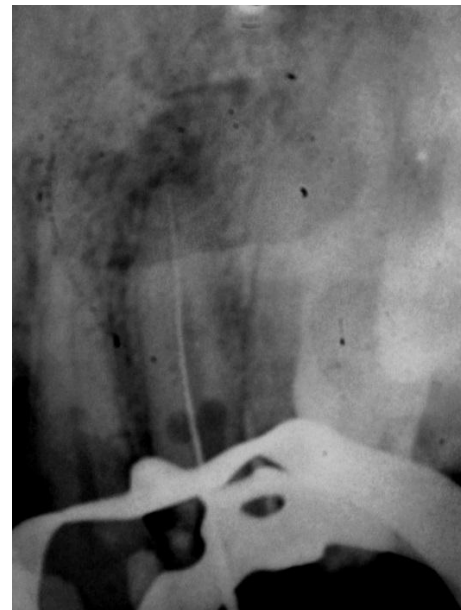

Figure 2 - Radiographic odontometry

After 30 days, the intracanal dressing was changed for another obtaining by mixing calcium hydroxide powder and iodoform, and the tooth was radiographed (figure 3) and submitted to computed tomography (figure 4) to prove the diagnosis.

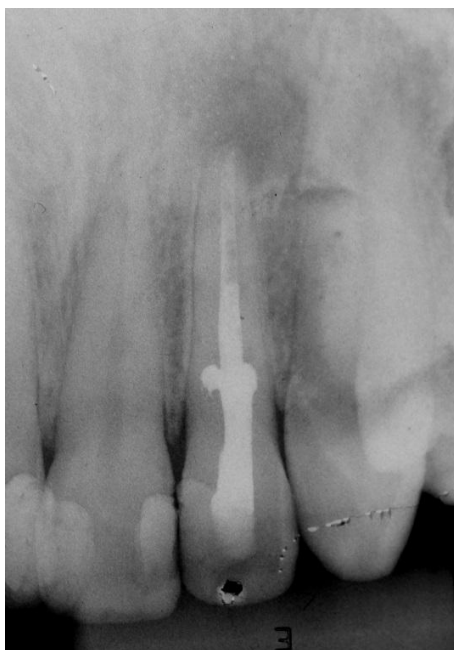

Figure 3 - Iodoform dressing

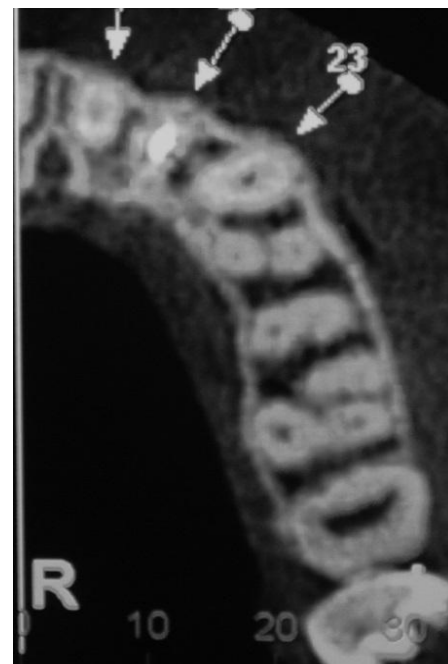


Figure 4 - Computed tomography

The intracanal dressing was monthly changed (calcium hydroxide) for 6 months, the time required for the patient to be submitted to the computed tomography to prove the diagnosis.

After that, the intracanal dressing was removed, and the canal was irrigated with 17% EDTA (Biodinâmica, Ibioporã, PR, Brazil), and this solution was kept into the canal for 5 min.

Root canal filling was executed through Tagger's hybrid technique, which is based on the association of the lateral condensation technique with the thermo-mechanic compaction technique (Mc Spadden). The main cone #70 was used. To perform the visual, tactile, and radiographic tests (figure 5), two accessory points size MF was used in the lateral condensation technique together with the calcium-hydroxide-based endodontic sealer Sealer 26 (Dentsply, Petrópolis, RJ, Brazil) and gutta-percha compactor size #80 (figure 6). After the filling procedure the gutta-percha excesses were cut with the aid of heat hand instrument. Then the pulp chamber was cleaned with 70% ethylic alcohol, sealed provisionally, and submitted to the final radiographic (figures 7, 8 and 9). The patient was referred for final restoration. The patient was called after three months for radiographic control (figure 10) and did not present any signs or symptoms.

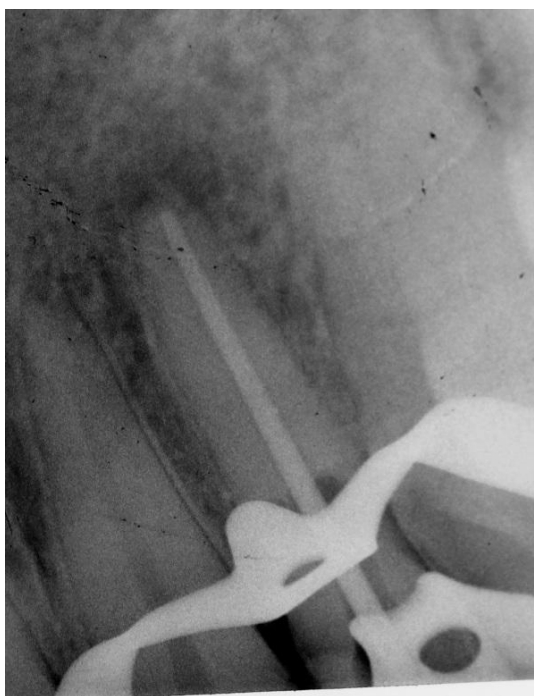


Figure 5 - Gutta-percha cone proof

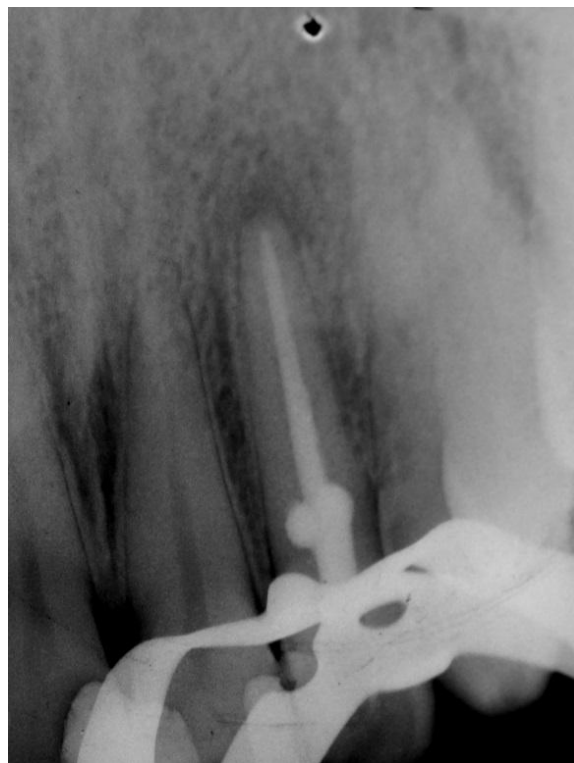


Figure 6 - Filling proof

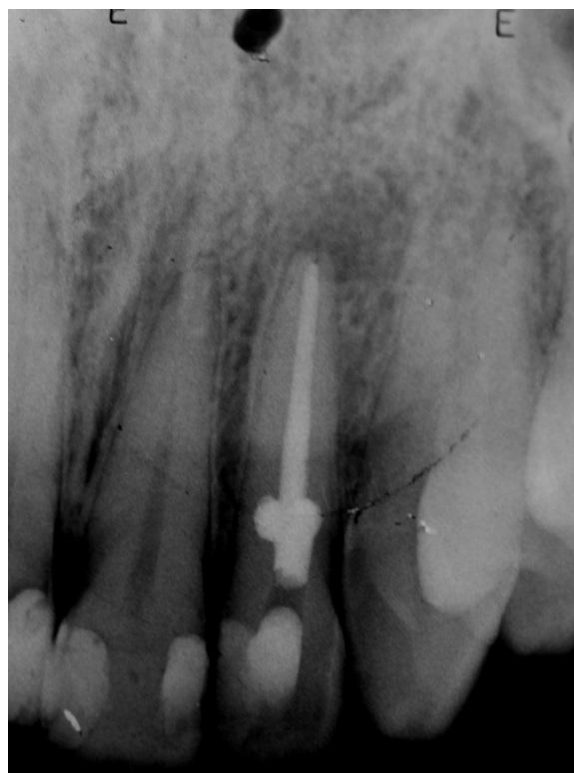

Figure 7 - Final ortho radiograph

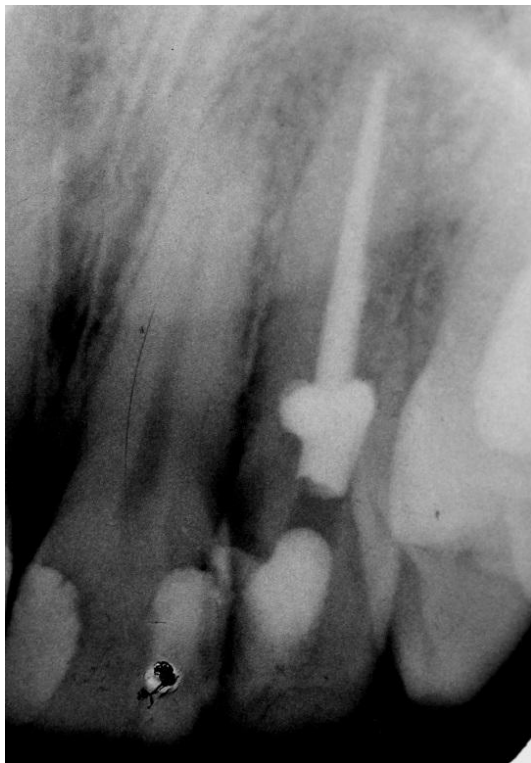

Figure 8 - Final mesial radiograph

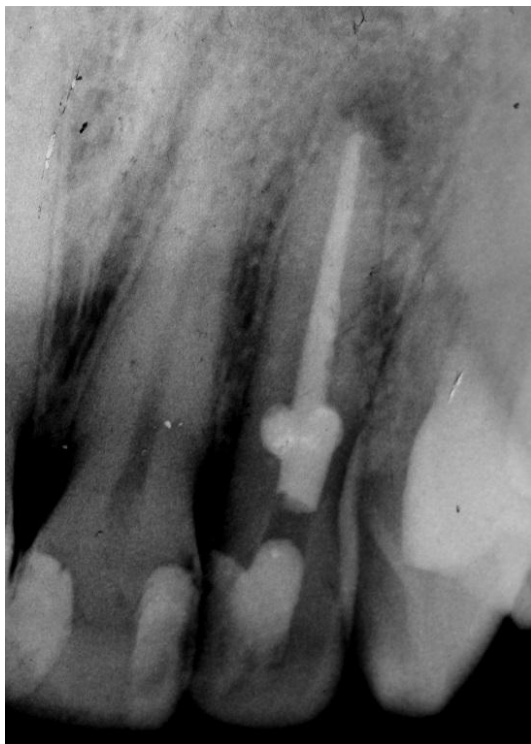

Figure 9 - Final distal radiograph

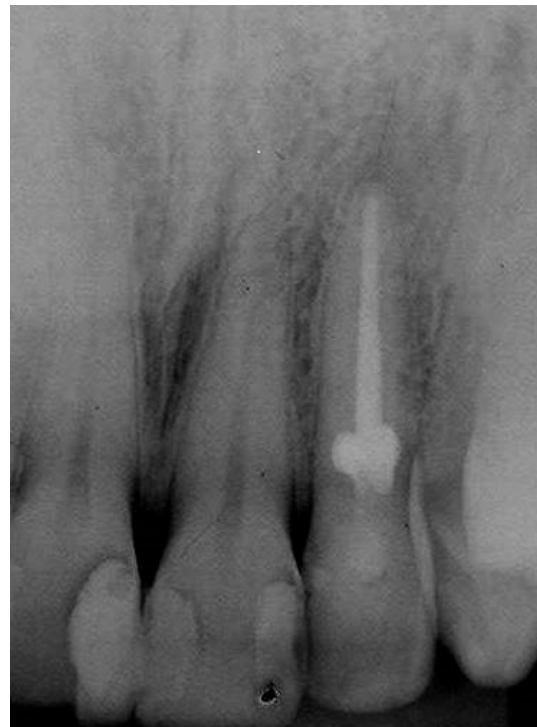

Figure 10 - 3-month following-up radiograph

Discussion

Lesion size has great influence on the outcome of treatment of teeth with internal resorption. Large lesions cause a reduction in tooth resistance that can lead to fracture. Therefore, it is important to start an endodontic treatment early, so as to stabilize the progression of the resorption process and prevent the root and/or crown of possible fractures [11].

Regarding the mechanical preparation, we chose the hand instruments, because of its satisfactory modeling and cleaning, and the radiographic image was of a straight and wide canal. We opted for the reverse enlargement technique (crown-down) together with the use of a sodium hypochlorite solution at 2.5%. The choice of the percentage of 2.5% sodium hypochlorite happened because the instrumentation time was longer than 30 min, which is equal to the dissolution capacity of the organic tissue of 5% sodium hypochlorite, thereby removing more than 90% of existing pulp tissue [6].

The intracanal dressing used was the calcium hydroxide because of its main anti-inflammatory, antibacterial actions, solvent of organic matter, neutralizing toxins, and stimulation of the repair of

calcified tissue. We emphasized the action of inhibiting resorption by increasing the pH of the medium, thus combating infection/inflammation [9].

The calcium hydroxide-based intracanal dressing intended to assist in the removal of the remaining pulp tissue, promote alkalization of the medium, favoring the stabilization of the resorption process, and can also be associated with iodoform to radiographically aid in tracking the area reabsorbed [2].

Calcium hydroxide is the most common temporary medication used as a dressing and is considered a conservative alternative treatment for bone and root resorption of endodontic origin [10]. It also has the ability to improve healing of periapical lesions. In addition, it penetrates through the dentinal tubules and increases the pH of cementum resorption areas. The alkalinity of the calcium hydroxide induces a necrosis area of the surface tissue and necrotic tissue that separates the material of vital tissues [7].

Another material that has properties well described in the literature, but has not been used frequently in the repair treatment of internal root resorption, is the mineral trioxide aggregate (MTA). MTA is a commonly used material for perforation repair, because it has many favorable properties such as a good seal ability, biocompatibility, radiopacity and moisture resistance [3].

MTA, because of its physical characteristics which ensure the expansion during fixation, which favor the sealing and maintenance of the biological properties showed by calcium hydroxide has some advantages when internal resorptions occur in the apical third of the root canal. MTA, when in contact with water, forms calcium oxide, which, when in contact with tissue fluids, forms calcium hydroxide and triggers the same process of tissue repair. [3]. In this clinical case, despite of the good indication of MTA, it was discarded because the root canal was not perforated and resorption was located at the cervical to medium third.

During the filling procedure, it is expected that the endodontist employs the filling techniques for the complex root canal system to perform better conditions of occupation and adaptation of the filling material, filling all the walls of the resorptive process [10].

Regarding the obturation techniques, although some studies report the injection of plasticized gutta-percha to complete the filling of the resorbed area, we chose the gutta-percha thermoplasticization with

McSpadden compactors following Tagger's hybrid technique, with a satisfactory result, since the full resorption area was filled with the material [2].

Conclusion

The correct initial examination, a very detailed and cautious thorough history and radiographic examinations are essential points for a correct diagnosis, treatment and, consequently, a better prognosis favoring the good outcome of the case.

According to the methodology, it was concluded that, after the three-month following-up after the endodontic treatment, the patient had stable internal resorption and regression of apical periodontitis, suggesting therapeutic success.

References

1. Almeida RR, Pinzan A, Almeida RR, Pinzan CRM. Idiopathic root resorption: report of a clinical case. *Revista Dental Press de Ortodontia e Ortopedia Facial*. 1999;4(5):35-40.
2. Barbizam JVB, Paranhos MPG, Filho MT. Internal dental resorption: root canal filling through the hybrid thermoplastic technique. *Rev Fac Odontol Lins Piracicaba*. 2003;15(1):7-10.
3. Brun DF, Scarparo RK, Kopper PMP, Grecca FS. Apical internal inflammatory root resorption and open apex treated with MTA: a case report. *Rev Odonto Ciên*. 2010;25(2):213-5.
4. Camargo SEA, Moraes MEL, Moraes LC, Camargo CHR. Principais características clínicas e radiográficas das reabsorções radiculares internas e externas. *Revista de Odontologia da Universidade Cidade de São Paulo*. 2008;20(2):195-203.
5. Consolaro A. O conceito de reabsorções dentárias ou as reabsorções dentárias não são multifatoriais, nem complexas, controversas ou polêmicas. *Dental Press J Orthod*. 2011;16(4):19-24.
6. Del Carpio-Perochena AE. Capacidade de dissolução do hipoclorito de sódio e da clorexidina sobre o biofilme oral formando "in situ". Bauru. Dissertação [Mestrado]. 2001.
7. Herrera H, Herrera H, Silva FWGP, Leonardo MR, Silva LAB. Reparo de lesão periapical extensa após utilização de curativo de demora à base de hidróxido de cálcio: relato de caso. *Rev Ciênc Odontol*. 2011;26(2):172-5.

8. Macieira MM, Justo AM, Só MVR, Santos MB, Magro ML, Kuga MC. Differential radiographic diagnosis of internal and external root resorptions between endodontic specialists and general practitioners. *RFO*;16(3):273-6.
9. Nery MJ, Cintra LTA, Gomes-Filho JE, Dezan-Junior E, Otoboni-Filho JA, Araujo GS et al. Longitudinal study of clinical-radiographic success of teeth treated with calcium hydroxide intracanal dressing. *Rev Odontol UNESP*. 2012;41(6):396-401.
10. Oliveira IKC, Travassos RMC, Malta CM, Sá RNS, Carvalho MGP, Dotto SR. Internal root resorption – a clinic case report. *Endodontia online*. 2014.
11. Yadav P, Rao Y, Jain A, Relhan N, Gupta S. Treatment of internal resorption with mineral trioxide aggregate: a case of report. *Journal Clinical Research and Diagnostics*. 2013;7(10):2400-1.
12. Torres EAD, Ronquiz L, Villar LSV. Reabsorção radicular: revisão de literatura. *Revista Científica Facimed*. 2011;3(3):90-103.
13. Vaz IP, Noites R, Ferreira JC, Pires P, Barros J, Carvalho MF. Treatment of upper central incisors after trauma. *RGO*. 2011;59(2):305-11.